

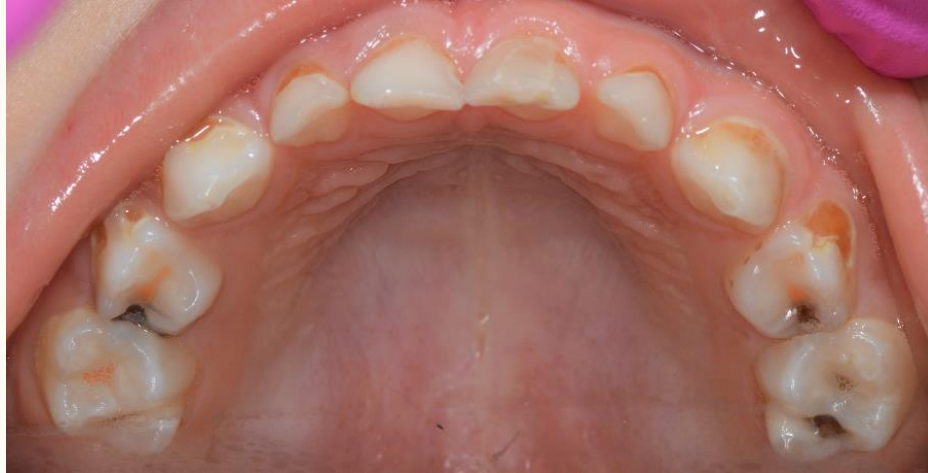

# SSC

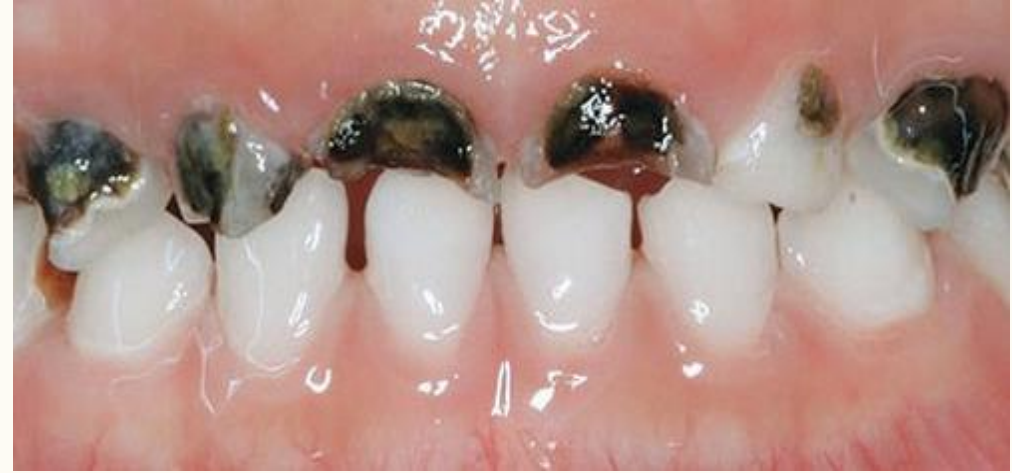STAINLESS STEEL CROWN

Chawisa Wongta, D.D.S.  
Taphanhin Crown Prince Hospital

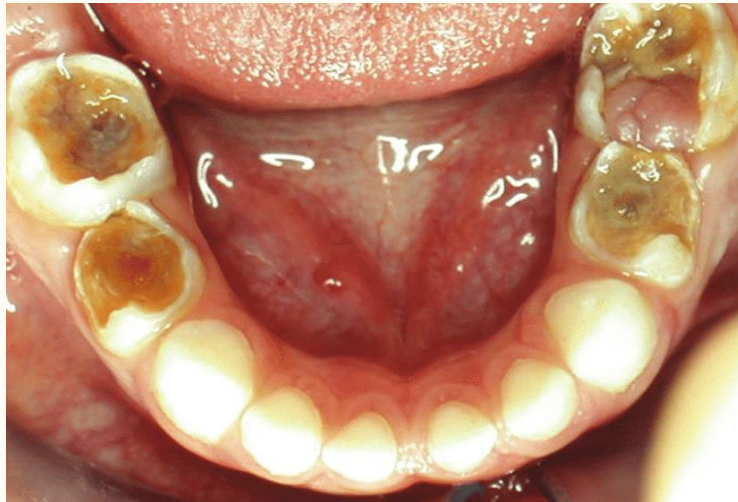# Introduction



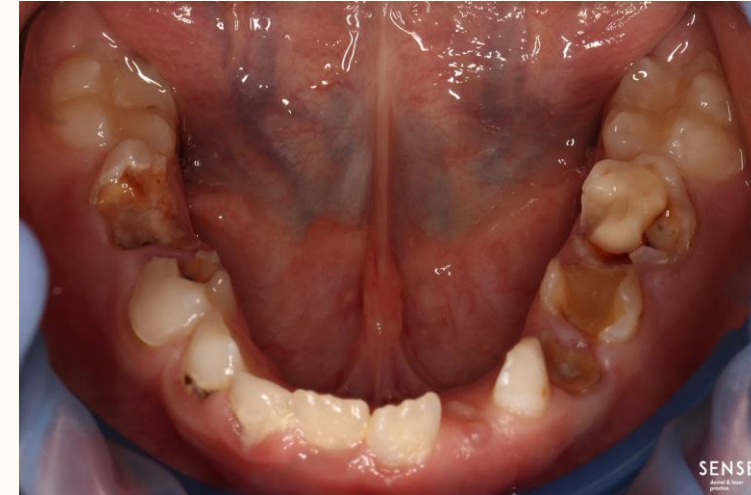[Why Should We Treat Primary Teeth With Dental Caries? — Kids Dental Tips](#)



[Rampant caries in Primary teeth - Academic Knowledge - Denteach](#)

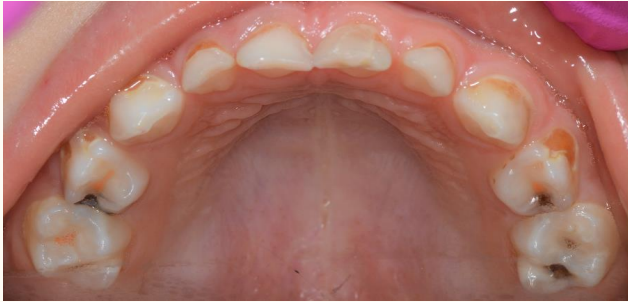

[Rampant caries in a child. \(Photograph courtesy of Dr. Ana Veira.\) | Download Scientific Diagram \(researchgate.net\)](#)

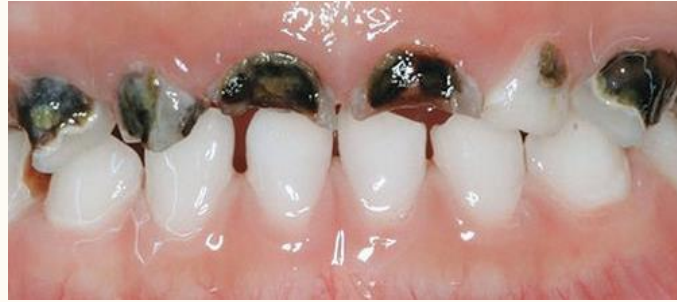

[SENSE](#)

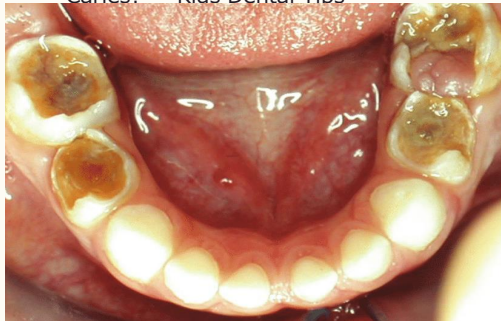
# Introduction



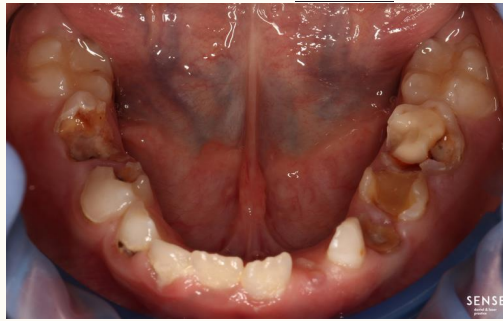[Why Should We Treat Primary Teeth With Dental Caries? — Kids Dental Tips](#)



[Rampant caries in Primary teeth - Academic Knowledge - Denteach](#)



[Rampant caries in a child. \(Photograph courtesy of Dr. Ana Veira.\) | Download Scientific Diagram \(researchgate.net\)](#)



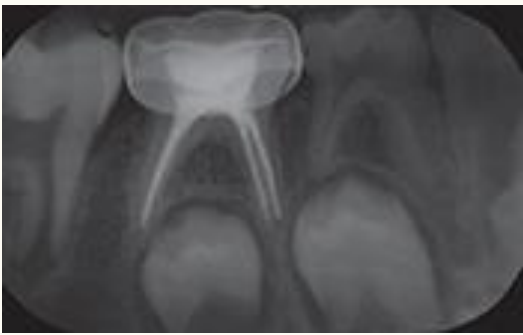[SENSE](#)



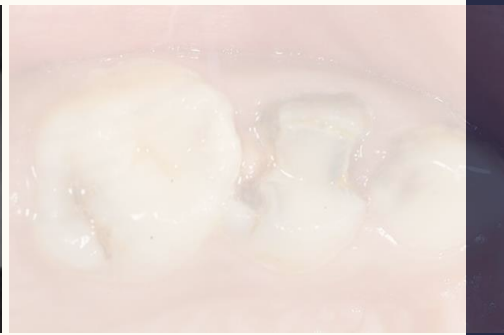# Indication



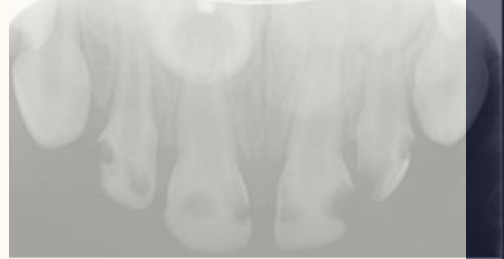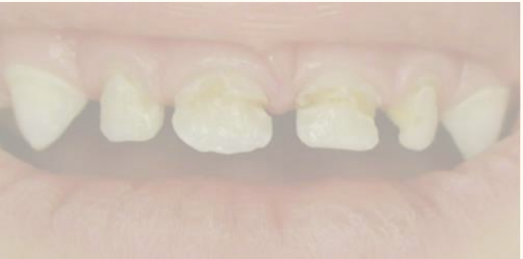- Following pulp therapy
- Multisurface caries restorations
- Patients at high risk of caries
- Deciduous teeth with developmental defects
  - amelogenesis imperfecta
  - dentinogenesis imperfecta
  - enamel hypoplasia
- Teeth with extensive wear
- Where it is likely that the restoration will fail, e.g., proximal box formed is extended beyond the anatomic line angles.
- Fractured teeth
- Patients who are unlikely to attend follow up appointments



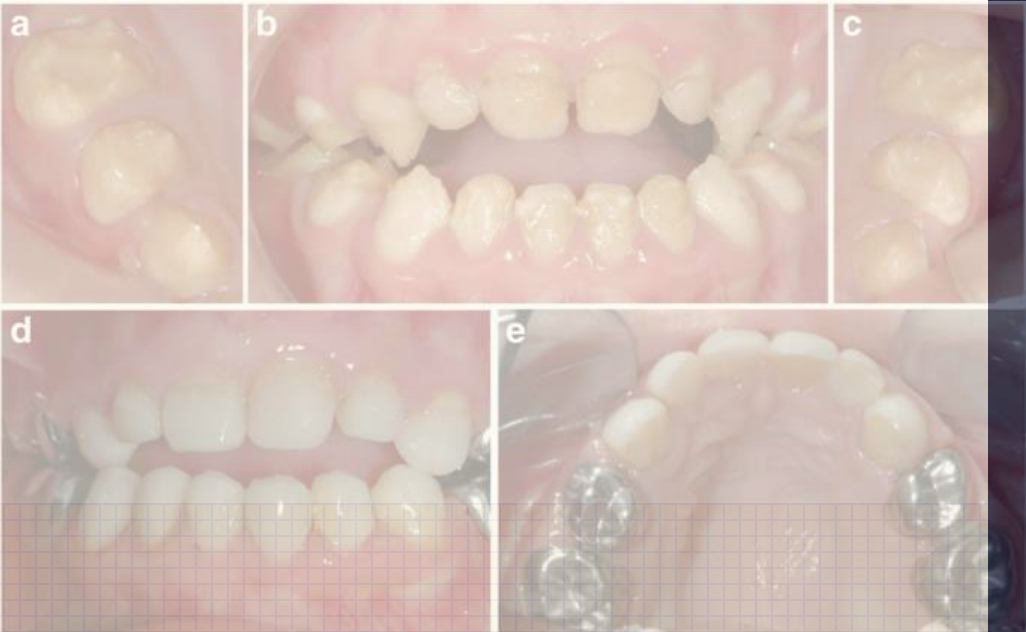
International Journal of Clinical Pediatric Dentistry (ijcpd.com)



Lesion Management: Selective Removal of Carious Tissue in Shallow, Moderately Deep, and Deep Carious Lesions | SpringerLink



[PDF] Evaluation of the Clinical Performance of Pedo Jacket Crowns in the Treatment of Maxillary Anterior Teeth with Early Childhood Caries: A Prospective Clinical and Laboratory Study. | Semantic Scholar

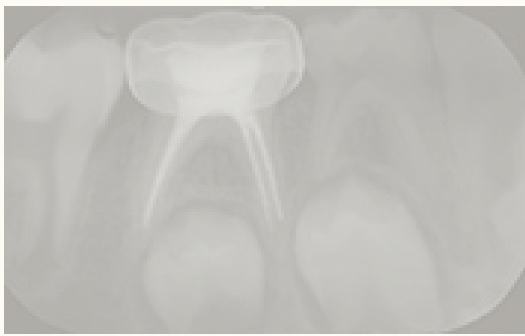


Amelogenesis imperfecta: therapeutic strategy from primary to permanent dentition across case reports | BMC Oral Health | Full Text (biomedcentral.com)

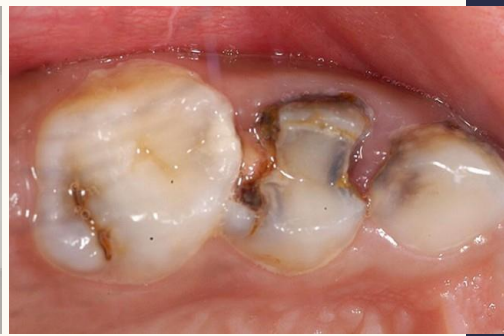# Indication



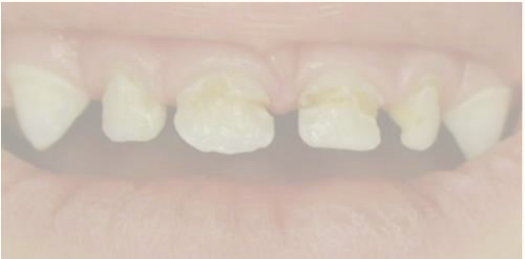- Following pulp therapy
- Multisurface caries restorations
- Patients at high risk of caries
- Deciduous teeth with developmental defects
  - amelogenesis imperfecta
  - dentinogenesis imperfecta
  - enamel hypoplasia
- Teeth with extensive wear
- Where it is likely that the restoration will fail, e.g., proximal box formed is extended beyond the anatomic line angles.
- Fractured teeth
- Patients who are unlikely to attend follow up appointments



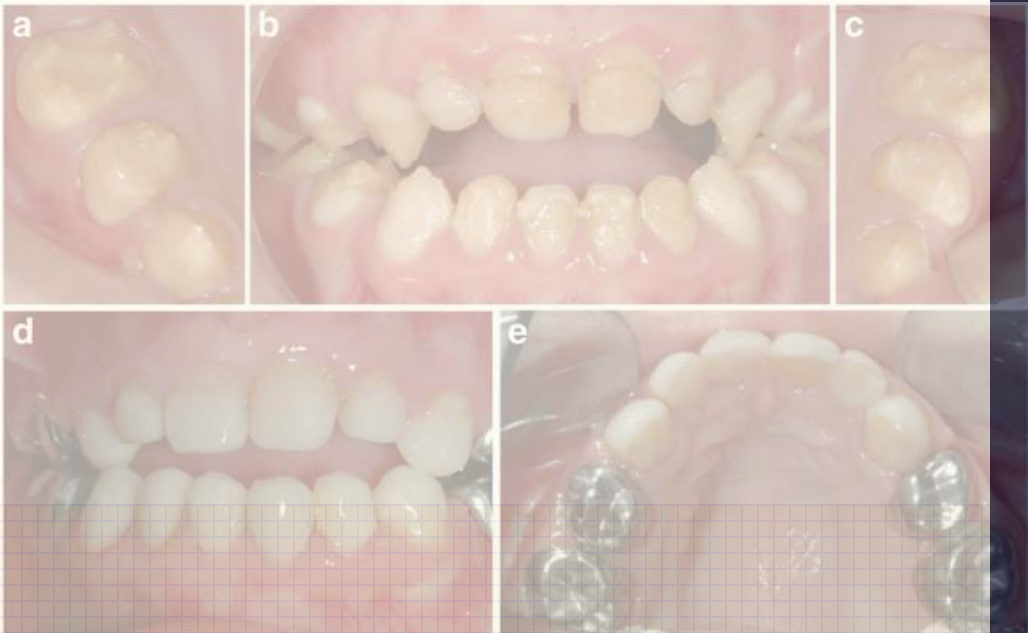
International Journal of Clinical Pediatric Dentistry (ijcpd.com)



Lesion Management: Selective Removal of Carious Tissue in Shallow, Moderately Deep, and Deep Carious Lesions | SpringerLink



[PDF] Evaluation of the Clinical Performance of Pedo Jacket Crowns in the Treatment of Maxillary Anterior Teeth with Early Childhood Caries: A Prospective Clinical and Laboratory Study. | Semantic Scholar



Amelogenesis imperfecta: therapeutic strategy from primary to permanent dentition across case reports | BMC Oral Health | Full Text (biomedcentral.com)

# Indication

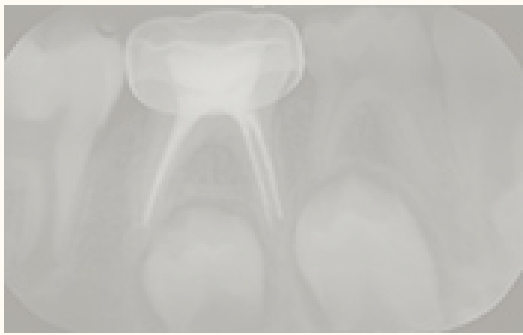


- Following pulp therapy
- Multisurface caries restorations
- Patients at high risk of caries
- Deciduous teeth with developmental defects
  - amelogenesis imperfecta
  - dentinogenesis imperfecta
  - enamel hypoplasia
- Teeth with extensive wear
- Where it is likely that the restoration will fail, e.g., proximal box formed is extended beyond the anatomic line angles.
- Fractured teeth
- Patients who are unlikely to attend follow up appointments

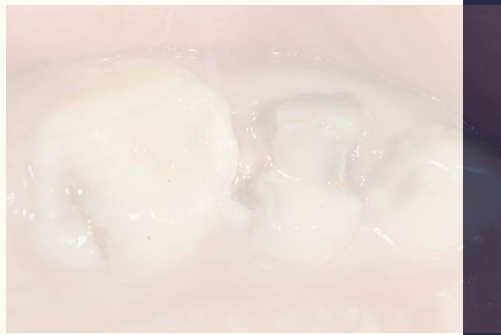# Indication



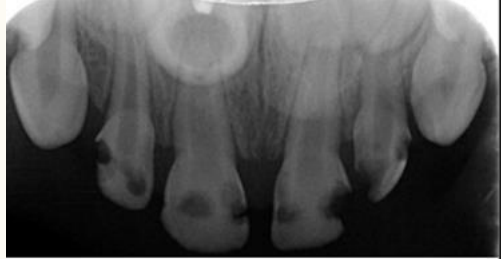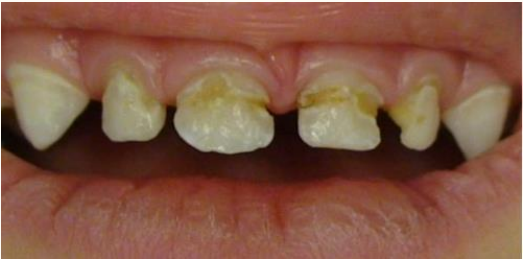- Following pulp therapy
- Multisurface caries restorations
- Patients at high risk of caries
- Deciduous teeth with developmental defects
  - amelogenesis imperfecta
  - dentinogenesis imperfecta
  - enamel hypoplasia
- Teeth with extensive wear
- Where it is likely that the restoration will fail, e.g., proximal box formed is extended beyond the anatomic line angles.
- Fractured teeth
- Patients who are unlikely to attend follow up appointments



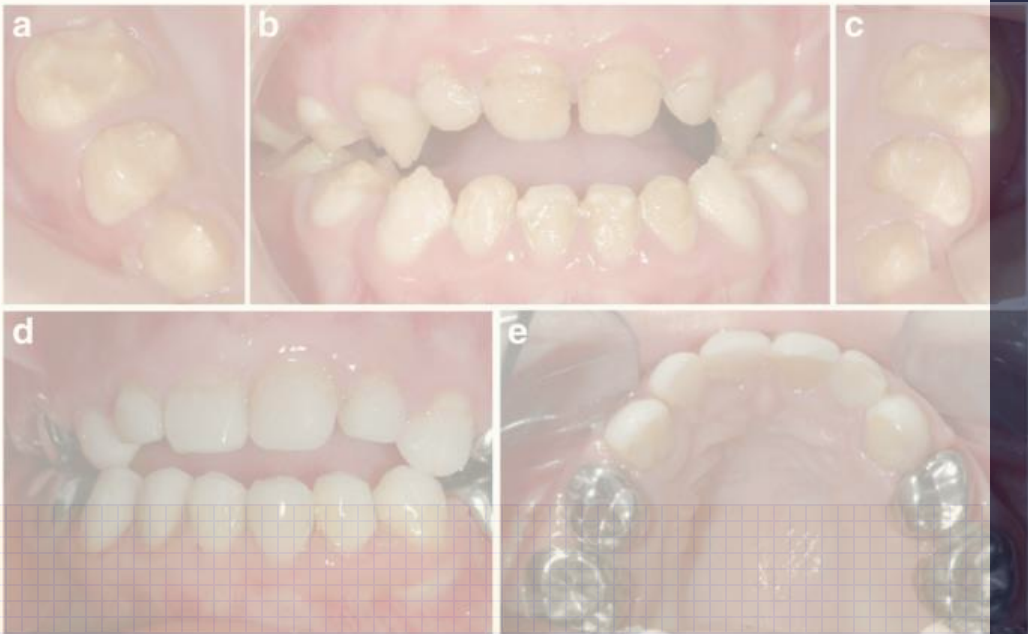
[International Journal of Clinical Pediatric Dentistry \(ijcpd.com\)](#)



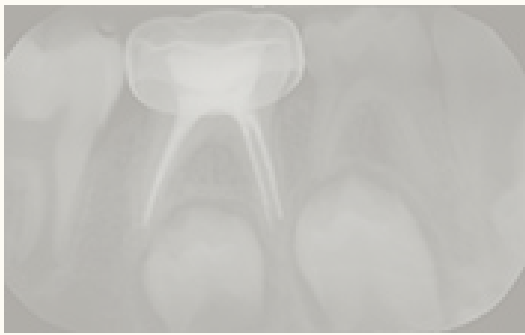
[Lesion Management: Selective Removal of Carious Tissue in Shallow, Moderately Deep, and Deep Carious Lesions | SpringerLink](#)



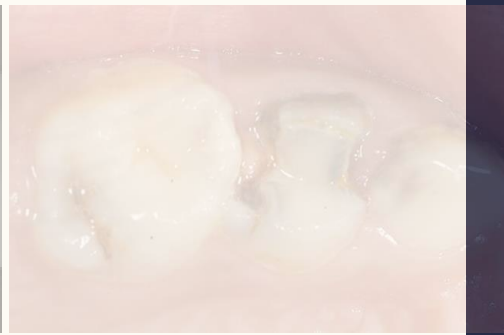[\[PDF\] Evaluation of the Clinical Performance of Pedo Jacket Crowns in the Treatment of Maxillary Anterior Teeth with Early Childhood Caries: A Prospective Clinical and Laboratory Study. | Semantic Scholar](#)



[Amelogenesis imperfecta: therapeutic strategy from primary to permanent dentition across case reports | BMC Oral Health | Full Text \(biomedcentral.com\)](#)



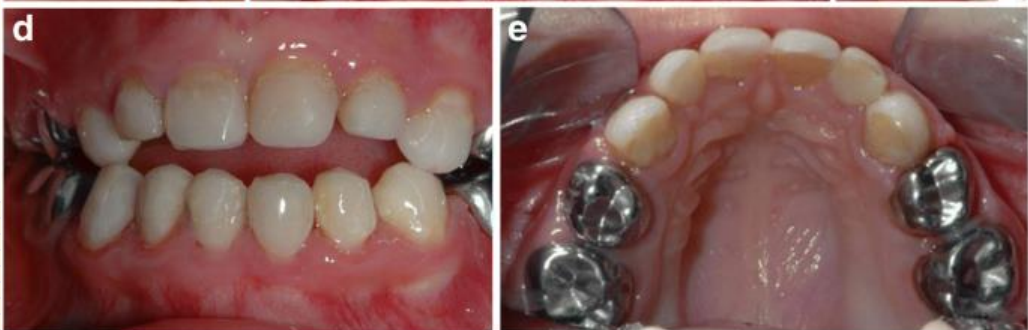
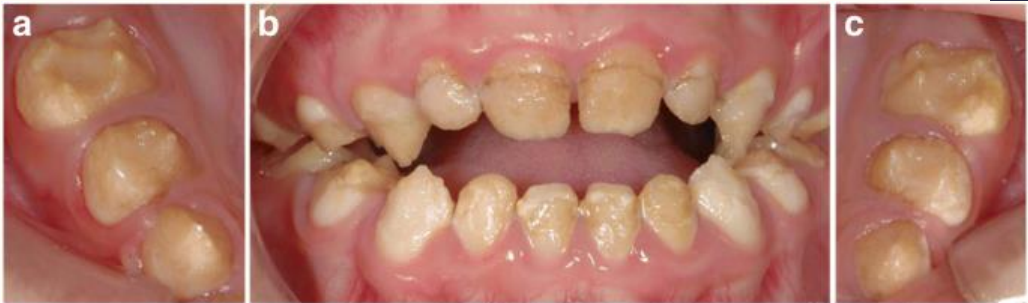International Journal of Clinical Pediatric Dentistry (ijcpd.com)



Lesion Management: Selective Removal of Carious Tissue in Shallow, Moderately Deep, and Deep Carious Lesions | SpringerLink



[PDF] Evaluation of the Clinical Performance of Pedo Jacket Crowns in the Treatment of Maxillary Anterior Teeth with Early Childhood Caries: A Prospective Clinical and Laboratory Study. | Semantic Scholar



Amelogenesis imperfecta: therapeutic strategy from primary to permanent dentition across case reports | BMC Oral Health | Full Text (biomedcentral.com)

# Indication

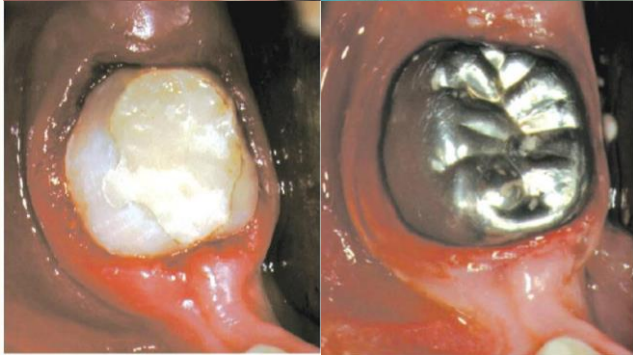
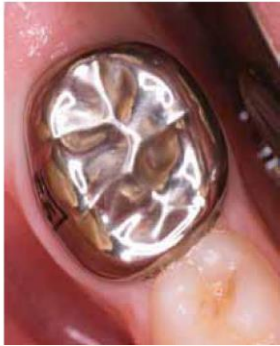
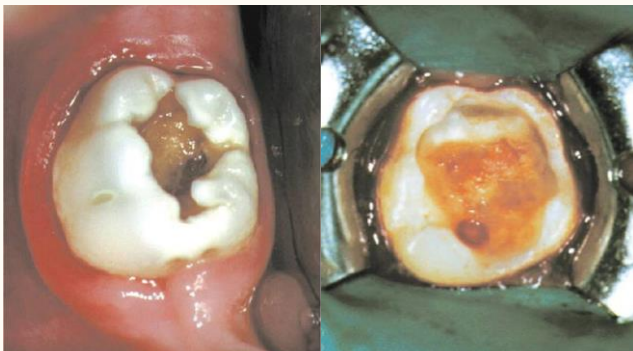
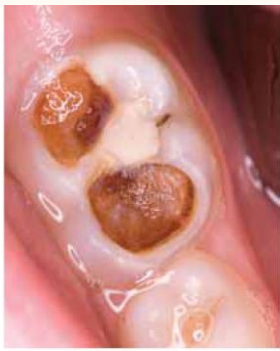- Following pulp therapy
- Multisurface caries restorations
- Patients at high risk of caries
- Deciduous teeth with developmental defects
  - amelogenesis imperfecta
  - dentinogenesis imperfecta
  - enamel hypoplasia
- Teeth with extensive wear
- Where it is likely that the restoration will fail, e.g., proximal box formed is extended beyond the anatomic line angles.
- Fractured teeth
- Patients who are unlikely to attend follow up appointments

# Indication

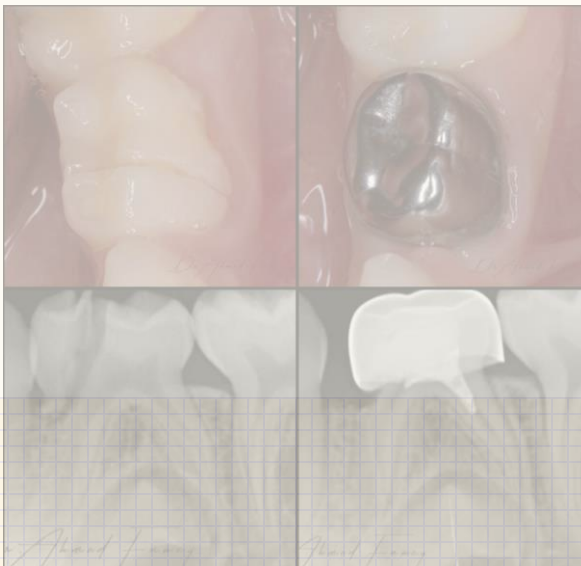


- Following pulp therapy
- Multisurface caries restorations
- Patients at high risk of caries
- Deciduous teeth with developmental defects
  - amelogenesis imperfecta
  - dentinogenesis imperfecta
  - enamel hypoplasia
- Teeth with extensive wear
- Where it is likely that the restoration will fail, e.g., proximal box formed is extended beyond the anatomic line angles.
- Fractured teeth
- Patients who are unlikely to attend follow up appointments



[dental-update.co.uk/content/cariology/should-deciduous-teeth-be-restored-reflections-of-a-cariologist/](https://dental-update.co.uk/content/cariology/should-deciduous-teeth-be-restored-reflections-of-a-cariologist/)

Diagnosis and Management of Dental Caries - Pediatric Dentistry - a Clinical Approach, 3ed. (doctorlib.info)

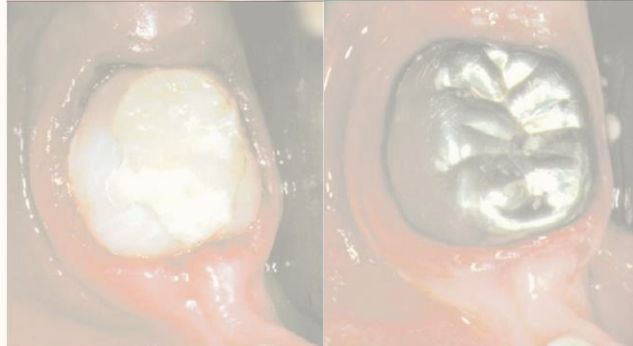
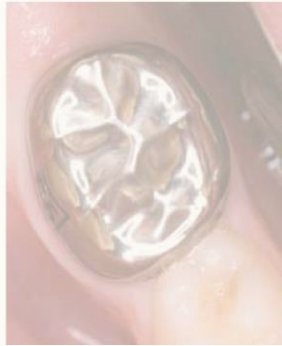
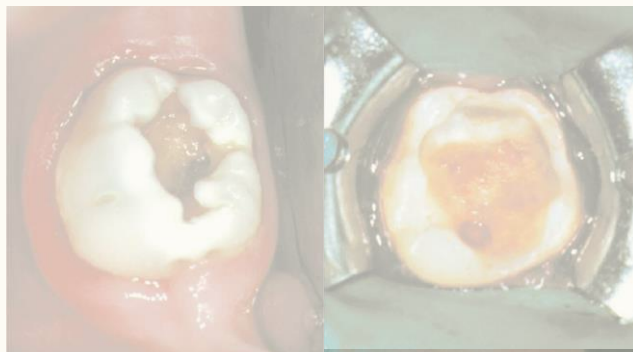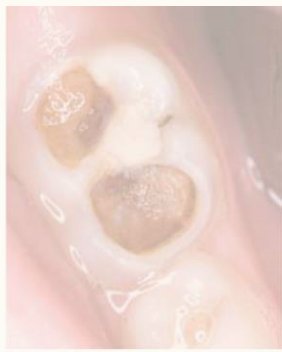(19) X (twitter.com)

# Indication

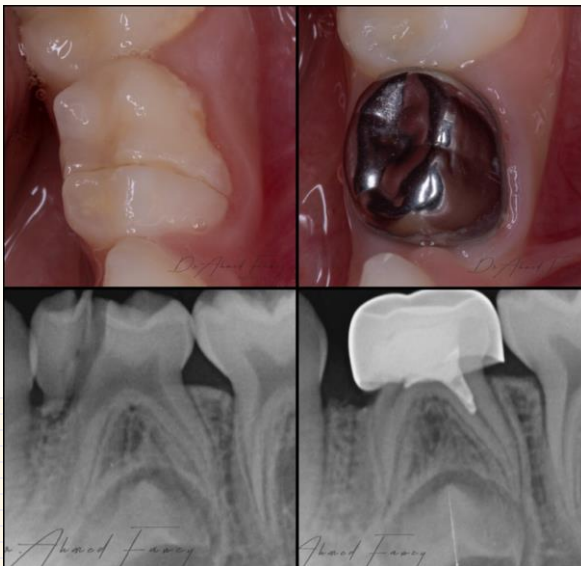

- Following pulp therapy
- Multisurface caries restorations
- Patients at high risk of caries
- Deciduous teeth with developmental defects
  - amelogenesis imperfecta
  - dentinogenesis imperfecta
  - enamel hypoplasia
- Teeth with extensive wear
- Where it is likely that the restoration will fail, e.g., proximal box formed is extended beyond the anatomic line angles.
- Fractured teeth
- Patients who are unlikely to attend follow up appointments



[dental-update.co.uk/content/cariology/should-deciduous-teeth-be-restored-reflections-of-a-cariologist/](https://dental-update.co.uk/content/cariology/should-deciduous-teeth-be-restored-reflections-of-a-cariologist/)

Diagnosis and Management of Dental Caries - Pediatric Dentistry - a Clinical Approach, 3ed. (doctorlib.info)

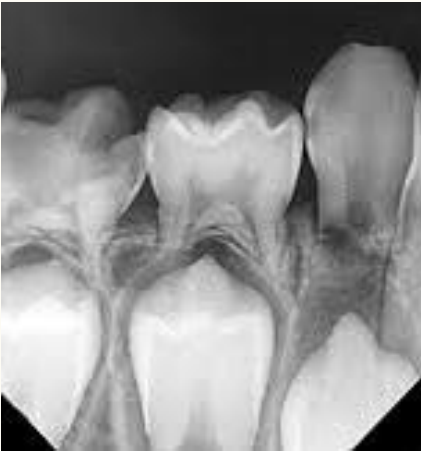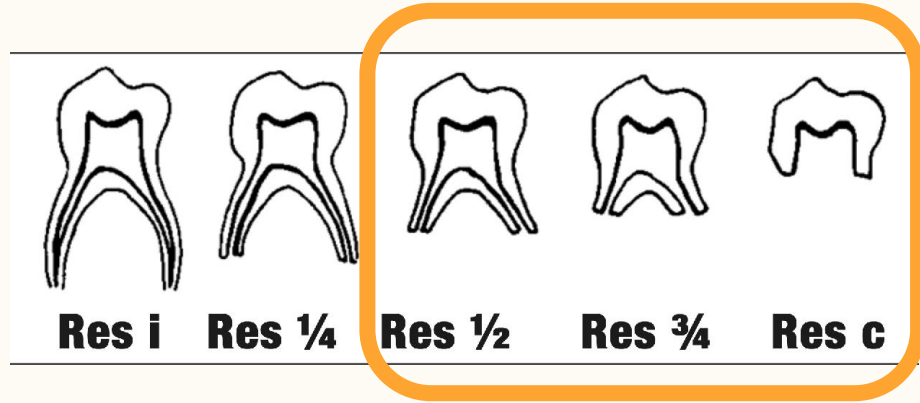


(19) X (twitter.com)

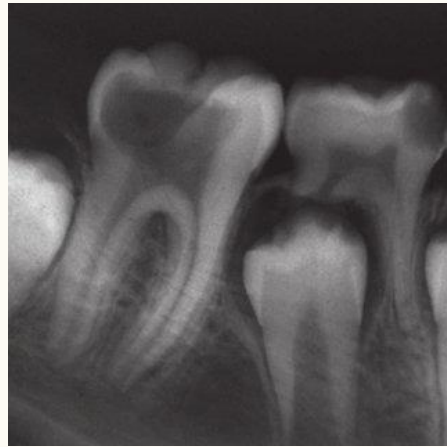

## Contraindication

- Primary teeth that exhibit more than a half of root resorption
- Primary tooth approaching exfoliation (6 to 12 months)
- The tooth is with excessive mobility
- Patients with nickel allergies and sensitivity
- Inability to fit the crown due to lack of cooperation by the patient



[PDF] Physiologic root resorption in primary teeth: molecular and histological events. | Semantic Scholar



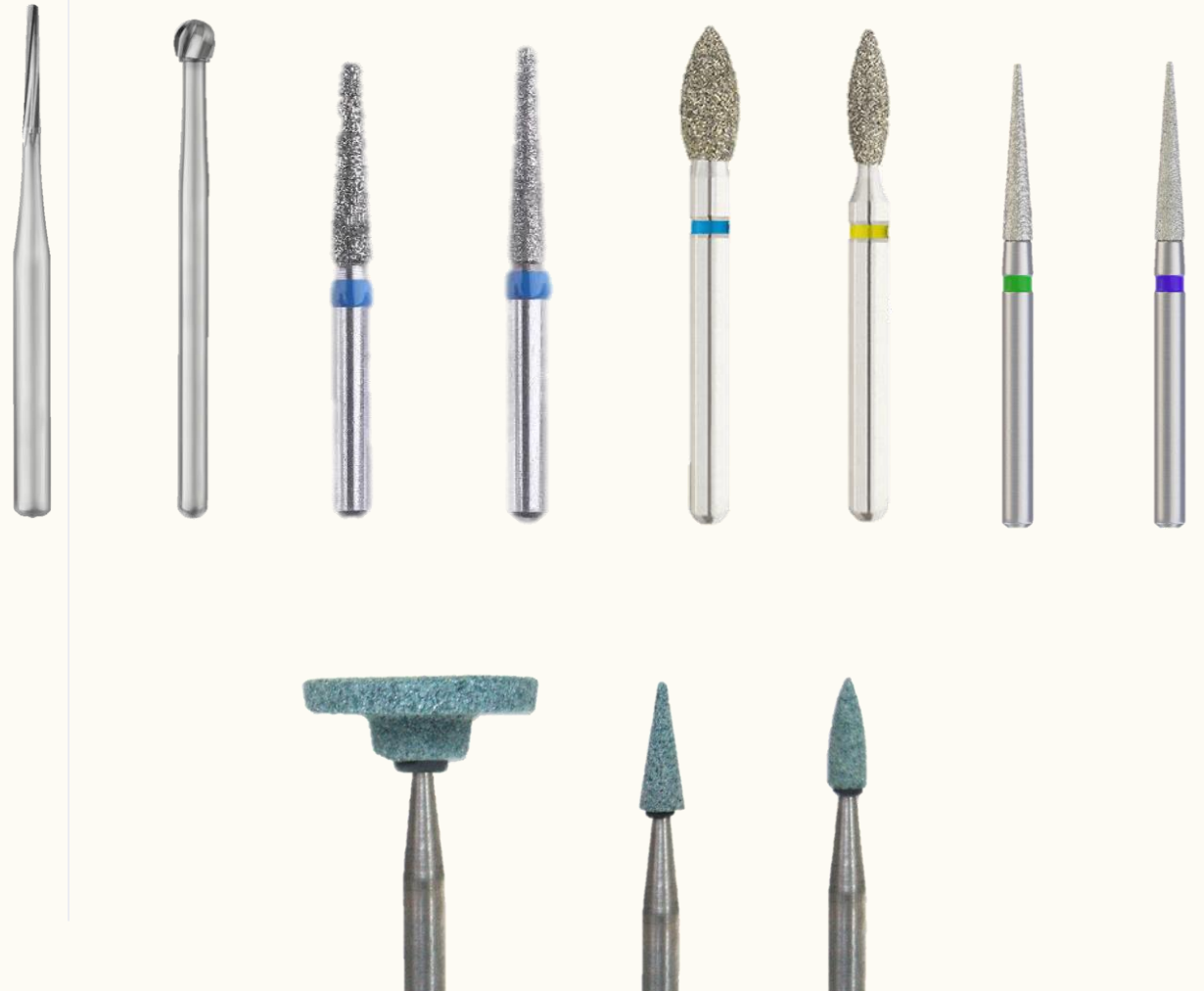[PDF] Asymmetrical root resorption in primary mandibular molars: Prevalence and determinants factors (researchgate.net)

# Armamentarium

# Armamentarium

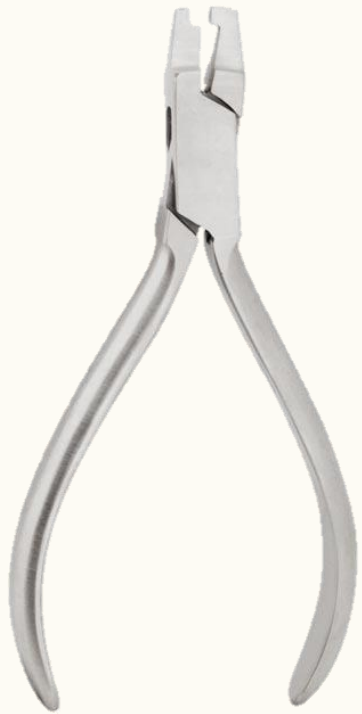## BURS AND STONES

- No. 169L or No. 69L F.G
- Round bur for removal of caries
- Flame shaped diamond bur or round end tapered bur
- Football-shaped diamond bur
- Long thin tapered bur
- Greenstone or heatless stone/rubber wheel stone
- Silicone bur

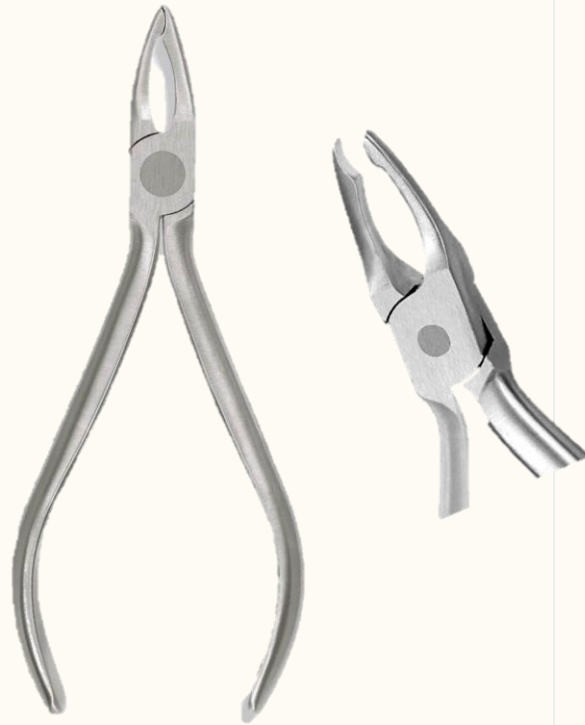

# Armamentarium

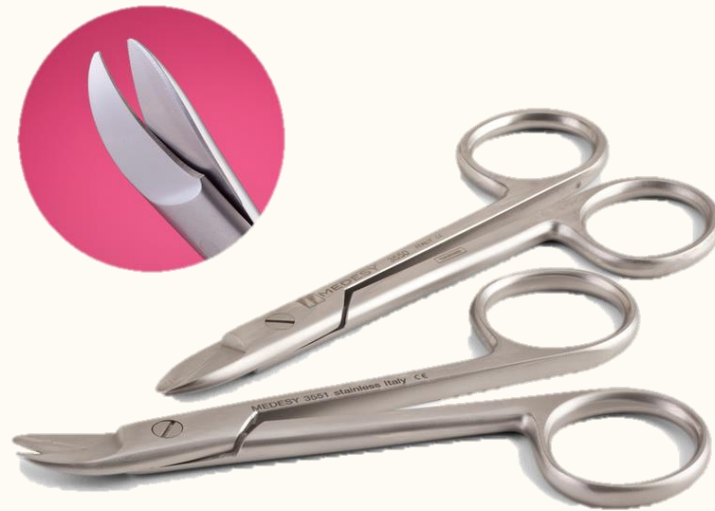## PLIERS AND INSTRUMENTS



- Crimping plier (no.800-417)



- Contouring plier (no.114)



- Scissor



# Armamentarium

## PLIERS AND INSTRUMENTS

- Spoon excavator
- Bite tab

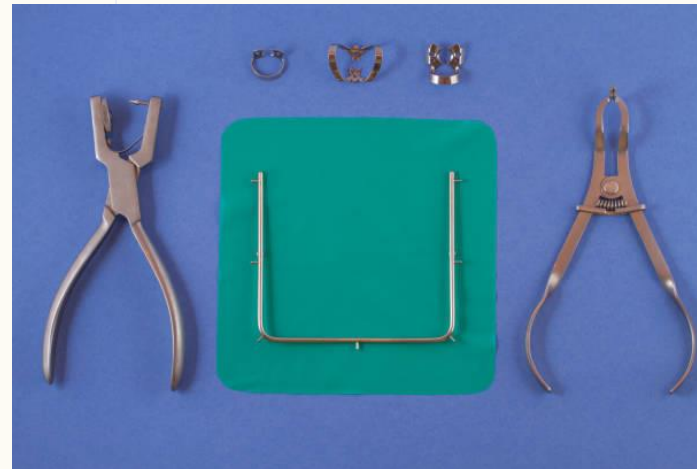


- Howe plier
- Contouring plier
- Scissor

# Armamentarium

## OTHERS


- Cement medium - glass slab/cement mixing pad, spatula, cement
- Rubber dam armamentarium
- Local anesthesia
- Dental floss
- Sharp explorer for marking the gingival extension of the crown margin



# Armamentarium



Size 4&5 most often used



# Clinical procedure

- Evaluate the preoperative occlusion
- Crown selection
- Administer local anesthesia
- +/- rubber dam isolation
- Tooth preparation
- Crown adaptation
- Crown finishing and polishing
- Crown cementation
- Post operative instruction

# Clinical procedure

- Evaluate the preoperative occlusion
- Crown selection
- Administer local anesthesia
- +/- rubber dam isolation
- Tooth preparation
- Crown adaptation
- Crown finishing and polishing
- Crown cementation
- Post operative instruction

- Dental midline

- Occlusion

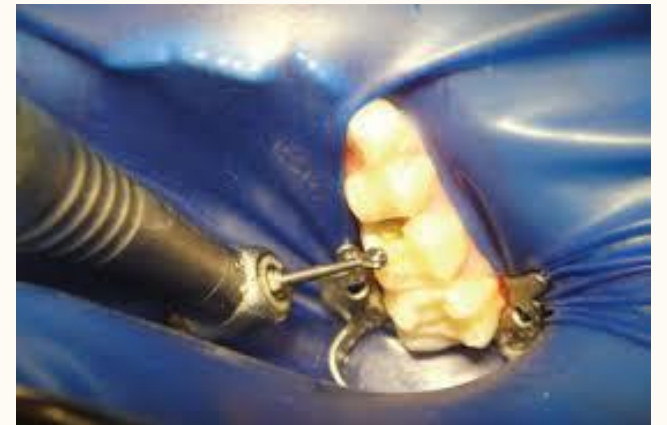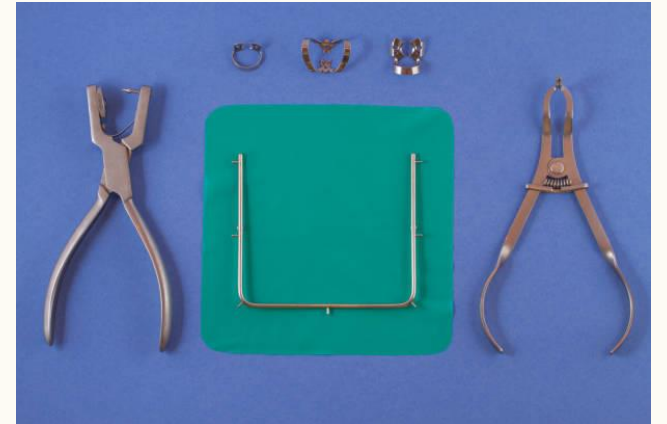


- Crown Selection  
(Measuring M-D dimensions)

- **\* If crown is not selected before tooth reduction, after tooth reduction it can be selected by trial and error procedure**

# Clinical procedure

- Evaluate the preoperative occlusion
- Crown selection
- **Administer local anesthesia**
- +/- rubber dam isolation
- Tooth preparation
- Crown adaptation
- Crown finishing and polishing
- Crown cementation
- Post operative instruction

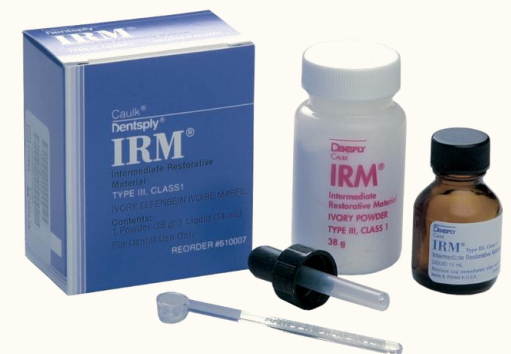

# Clinical procedure

- Evaluate the preoperative occlusion
- Crown selection
- Administer local anesthesia
- +/- rubber dam isolation
- **Tooth preparation**
- Crown adaptation
- Crown finishing and polishing
- Crown cementation
- Post operative instruction

## Aim of tooth preparation

- To remove complete caries
- To provide sufficient space for SSC
- To have sufficient tooth for retention of crown
- **After caries removal or pulp therapy, the previously carious area can be built up with "IRM"**



# Clinical procedure

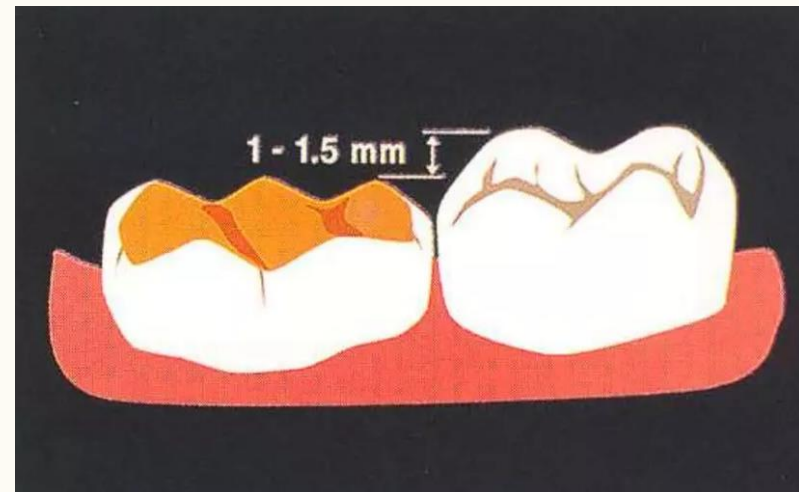
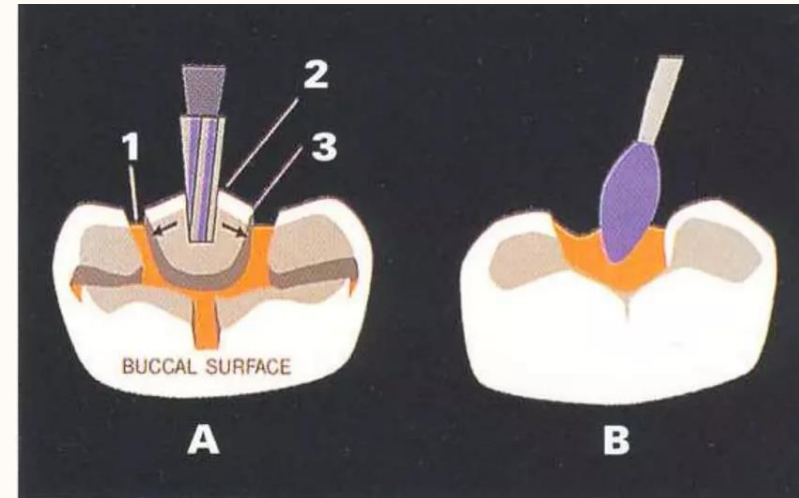
## Tooth preparation

- Occlusal reduction
  - Proximal reduction
  - Beveling
  - Round all sharp line angles & corners
- 
- **Buccal & lingual reduction only if it is needed**

# Clinical procedure

## Tooth preparation

- Occlusal reduction
- Proximal reduction
- Beveling
- Round all sharp line angles & corners
- Buccal & lingual reduction only if it is needed

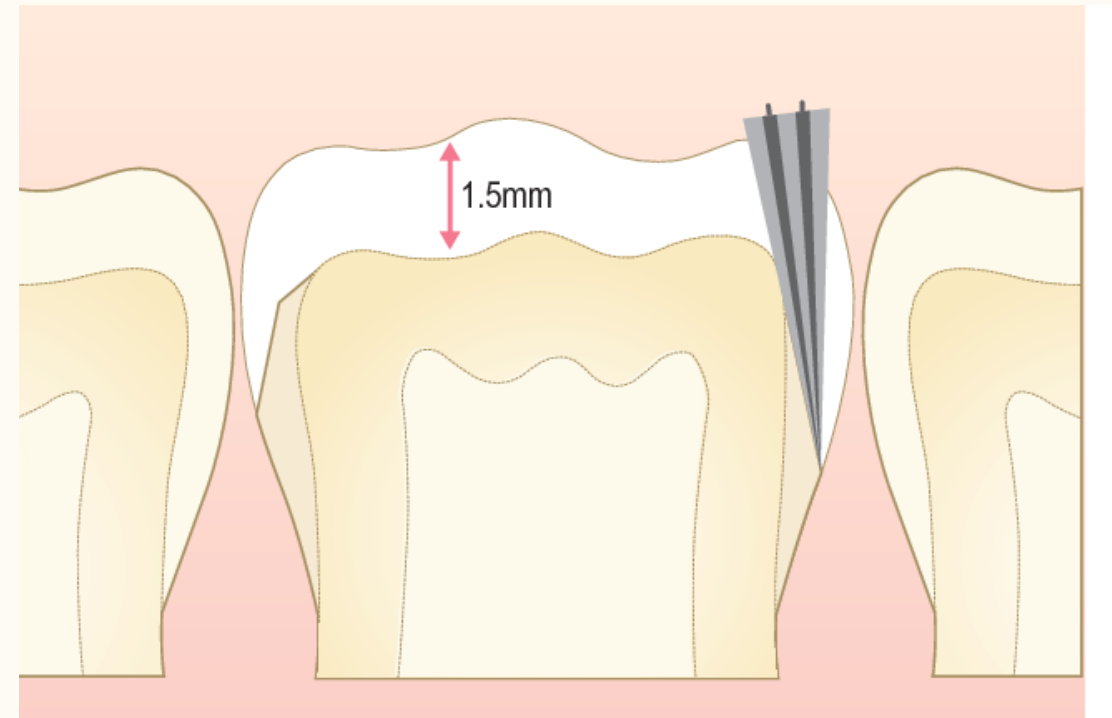


# Clinical procedure

## Tooth preparation

- Occlusal reduction
  - Proximal reduction
  - Beveling
  - Round all sharp line angles & corners
- 
- Buccal & lingual reduction only if it is needed

“ Feather or knife edge ”

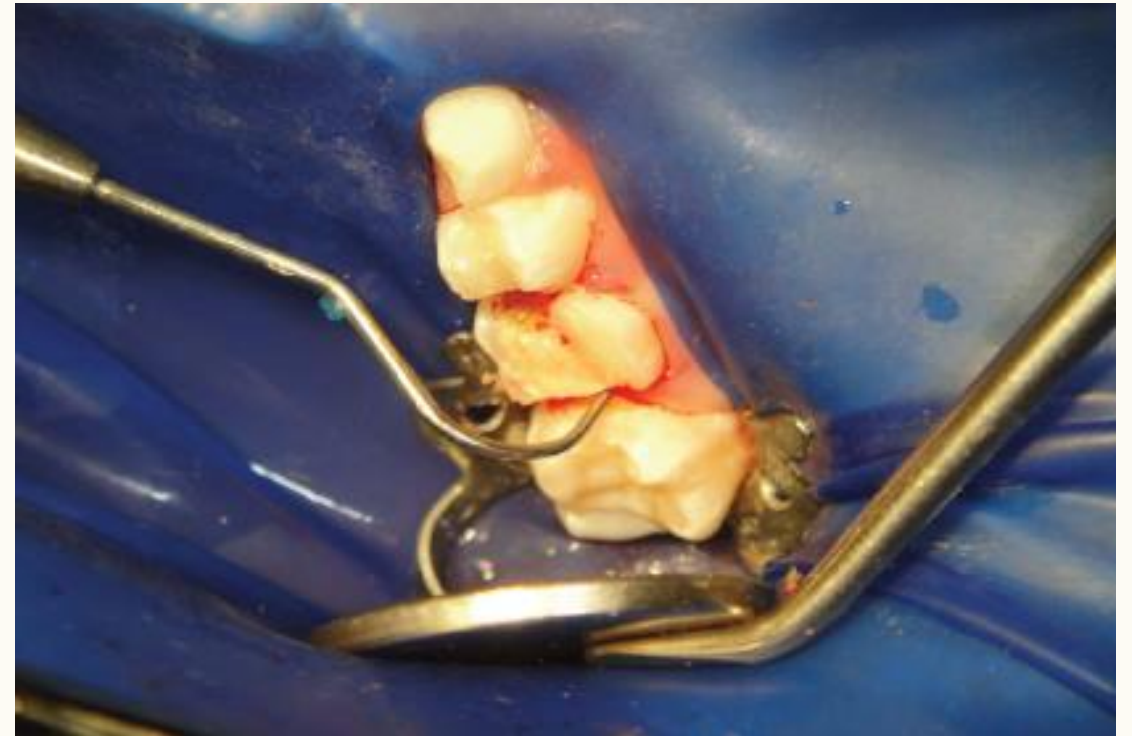

# Clinical procedure

## Tooth preparation

- Occlusal reduction
- Proximal reduction
- Beveling
- Round all sharp line angles & corners
- Buccal & lingual reduction only if it is needed

“ check with explorer”

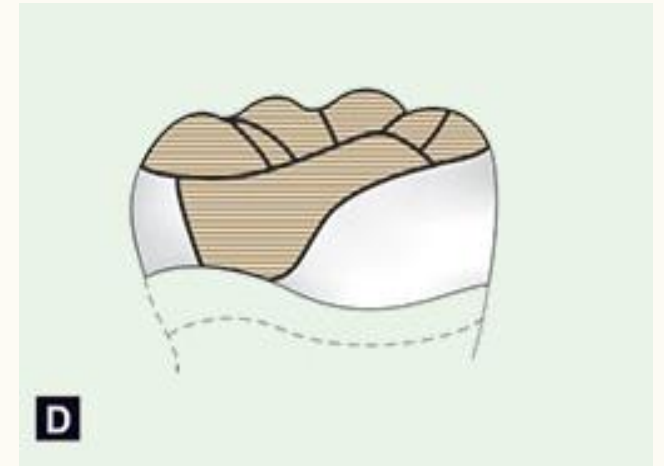
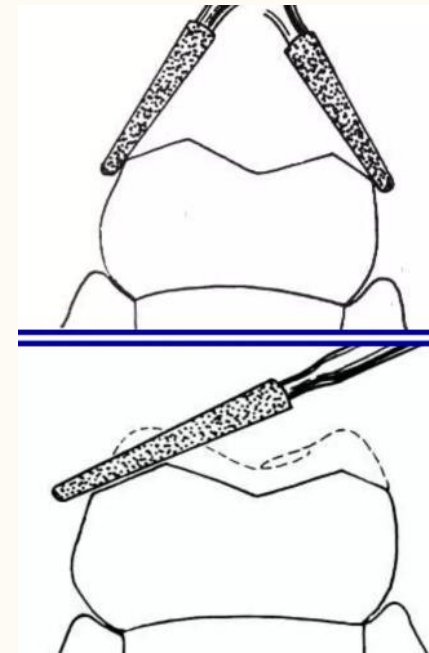


Full coverage restoration for primary molars | Pocket Dentistry

# Clinical procedure

## Tooth preparation

- Occlusal reduction
  - Proximal reduction
  - Beveling
  - Round all sharp line angles & corners
- 
- Buccal & lingual reduction only if it is needed

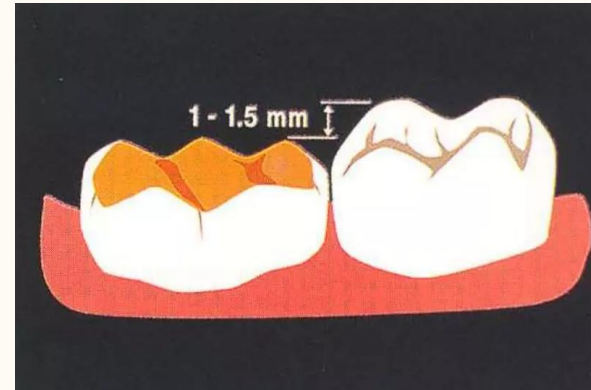


77-1.jpg (460×347) (d45jl3w9libvn.cloudfront.net)

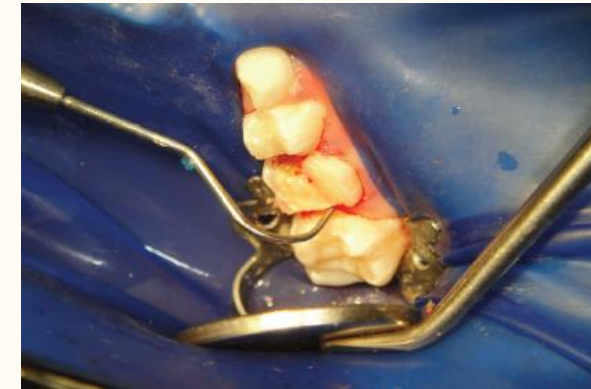# Clinical procedure

## Evaluation of tooth preparation

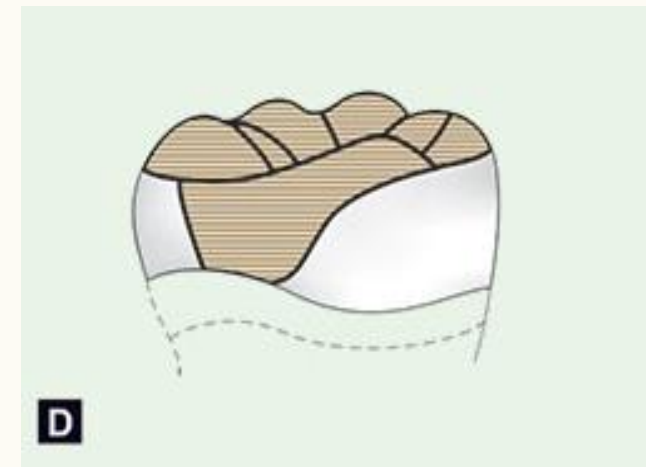
- Occlusal clearance 1-1.5 mm.
- Proximal reduction
- Buccal & Lingual surface if required reduced 0.5 mm. with feather edge margin
- Buccal & Lingual surface coverage slightly toward occlusal
- All line & point angles rounded



Stainless steel crowns in Pediatric Dentistry | PPT (slideshare.net)



Full coverage restoration for primary molars | Pocket Dentistry




77-1.jpg (460x347) (d45jl3w9libvn.cloudfront.net)

# Clinical procedure

- Evaluate the preoperative occlusion
- Crown selection
- Administer local anesthesia
- +/- rubber dam isolation
- Tooth preparation
- **Crown adaptation**
- Crown finishing and polishing
- Crown cementation
- Post operative instruction

## Crown should have

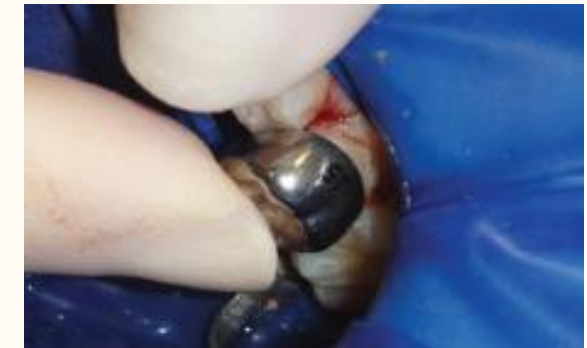
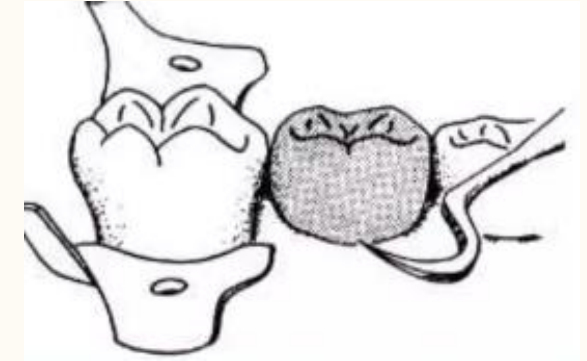
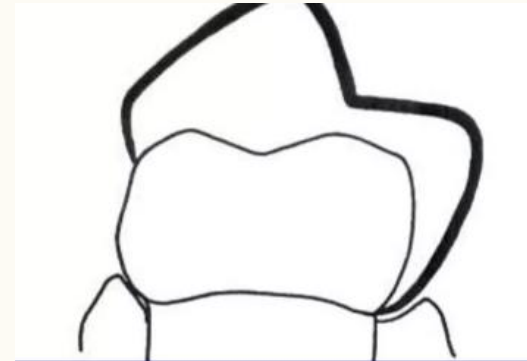
- **Tight snap fit**
- **Restore origin contour & occlusal anatomy**
- **Smallest crown that well fit**
- **Usually no.4 & 5 commonly used**



# Clinical procedure

## Crown adaptation

- Try crown on tooth: lingual to buccal
- Mark scratch line
- Cut 1 mm. below with scissors
- Place crown again:
  - If blanching seen: re-scratch & retrim

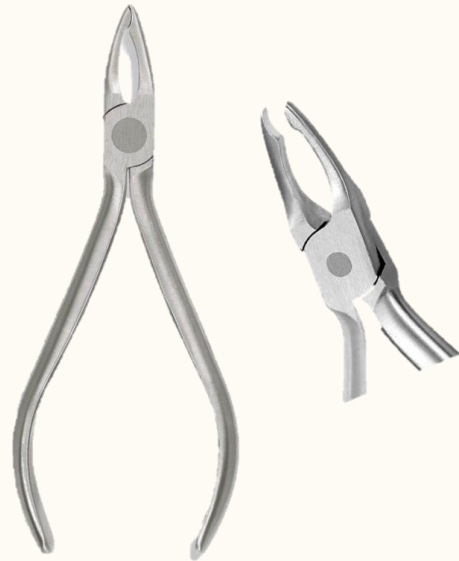

Full coverage restoration for primary molars | Pocket Dentistry

# Clinical procedure

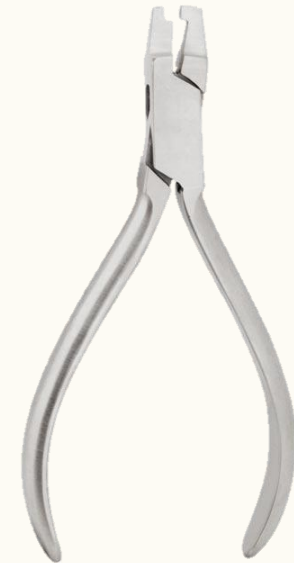## Crown adaptation

- **Contouring**



- Contour 1/3 cervical of the buccal & lingual surfaces

- **Crimping**

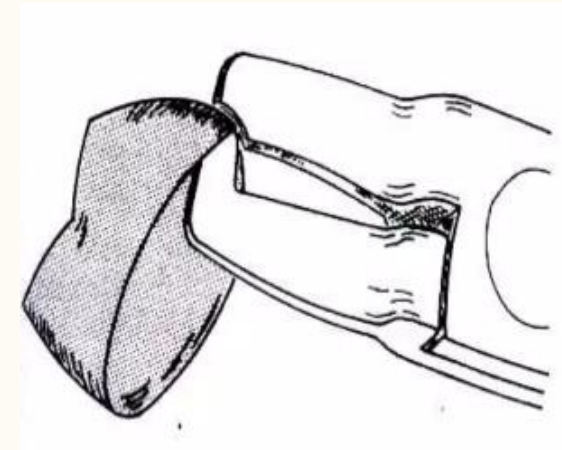
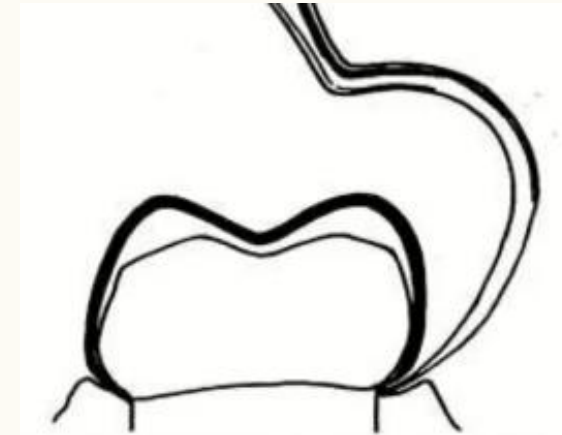


- Crimp cervical margin 1 mm. circumferentially

# Clinical procedure

## Evaluation

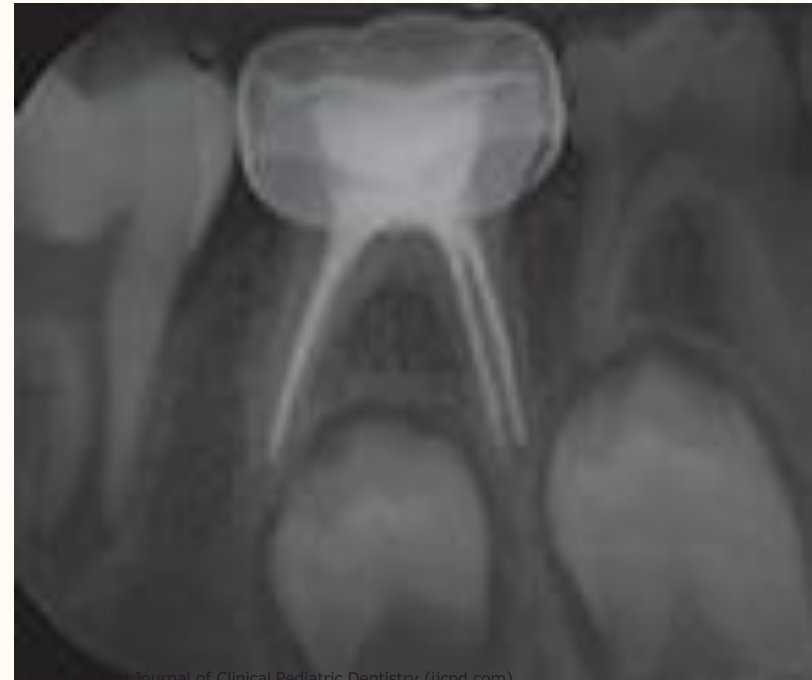- Check with explorer
  - If margin open: recrimp
  - If overextended: start again
- Resistance to seat
  - Without blanching: **ledges**
  - With blanching: **crown too wide, too long**



# Clinical procedure

## Radiographic Evaluation


- To verify the gingival contour and extension
- To ensure the complete coverage of the tooth



# Clinical procedure

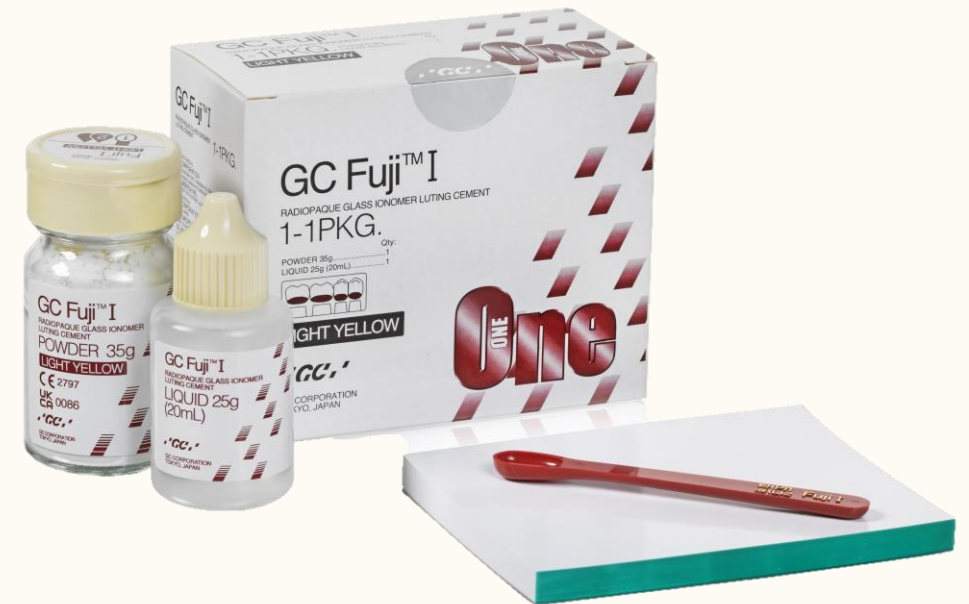- Evaluate the preoperative occlusion
- Crown selection
- Administer local anesthesia
- +/- rubber dam isolation
- Tooth preparation
- Crown adaptation
- **Crown finishing and polishing**
- Crown cementation
- Post operative instruction

- **Green stone: knife-edge finish cervically**
- **Rubber wheel: to smoothen the margins**
- **Silicone bur: polishing**



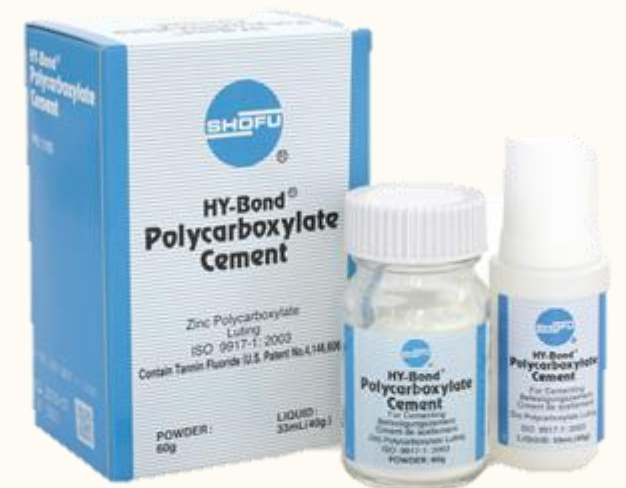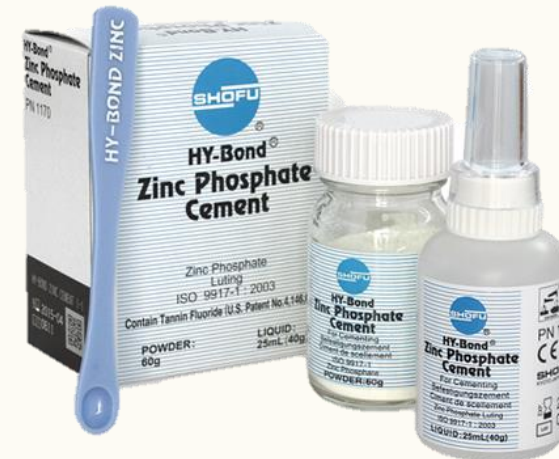# Clinical procedure

- Evaluate the preoperative occlusion
- Crown selection
- Administer local anesthesia
- +/- rubber dam isolation
- Tooth preparation
- Crown adaptation
- Crown finishing and polishing
- **Crown cementation**
- Post operative instruction



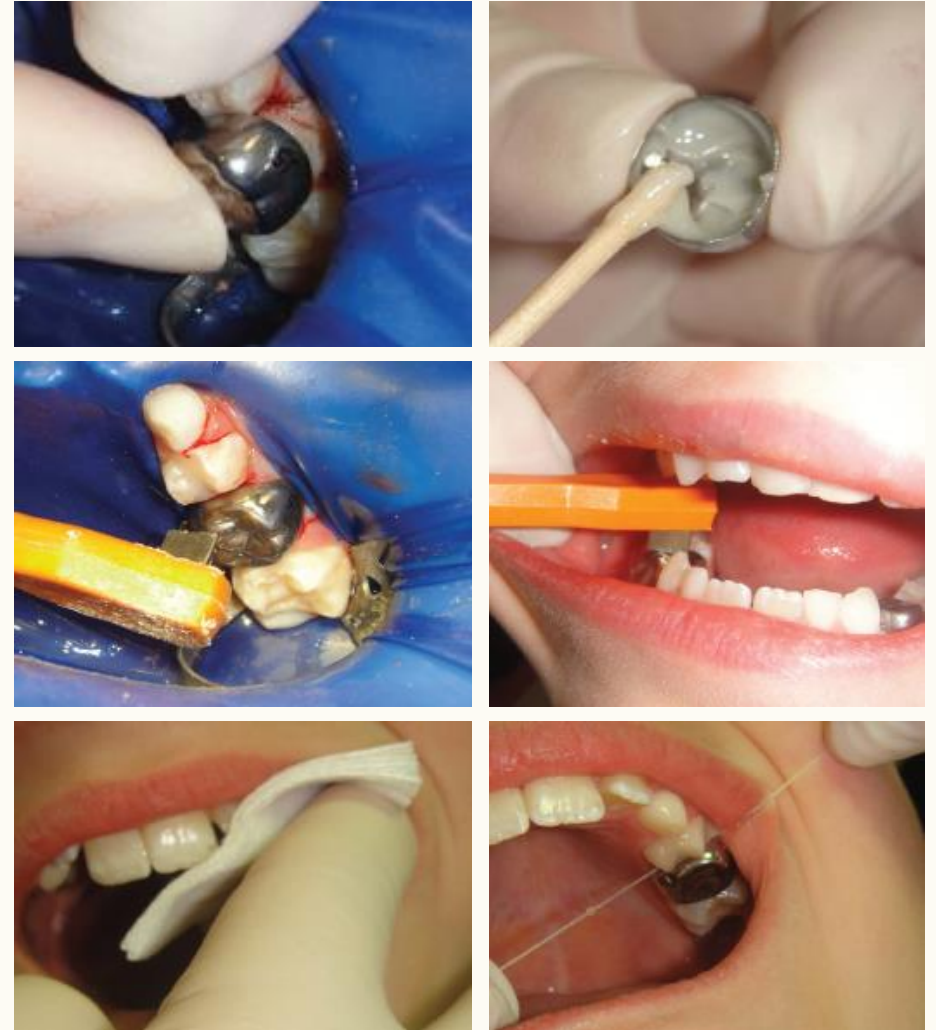# Clinical procedure

- Evaluate the preoperative occlusion
- Crown selection
- Administer local anesthesia
- +/- rubber dam isolation
- Tooth preparation
- Crown adaptation
- Crown finishing and polishing
- **Crown cementation**
- Post operative instruction



# Clinical procedure

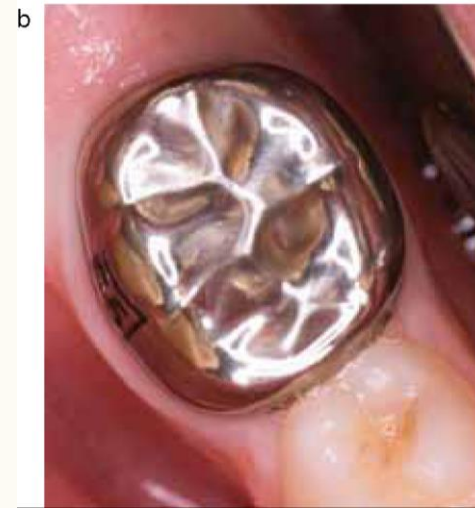
- Evaluate the preoperative occlusion
- Crown selection
- Administer local anesthesia
- +/- rubber dam isolation
- Tooth preparation
- Crown adaptation
- Crown finishing and polishing
- **Crown cementation**
- Post operative instruction



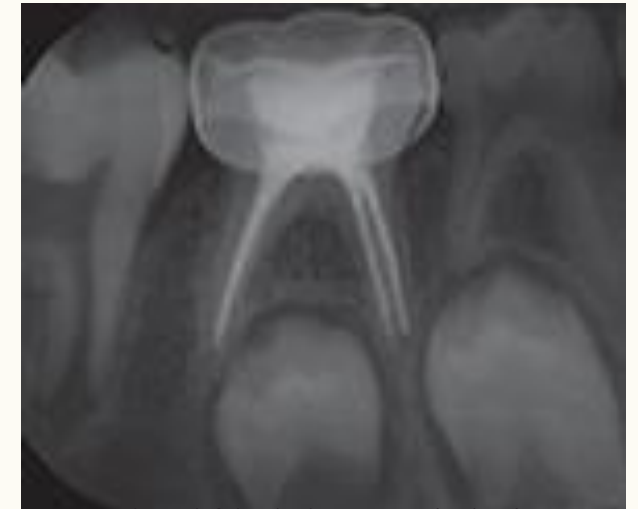# Clinical procedure

- Evaluate the preoperative occlusion
- Crown selection
- Administer local anesthesia
- +/- rubber dam isolation
- Tooth preparation
- Crown adaptation
- Crown finishing and polishing
- **Crown cementation**
- Post operative instruction

## Clinically & Radiographic evaluation



[dental-update.co.uk/content/cariology/should-deciduous-teeth-be-restored-reflections-of-a-cariologist/](http://dental-update.co.uk/content/cariology/should-deciduous-teeth-be-restored-reflections-of-a-cariologist/)



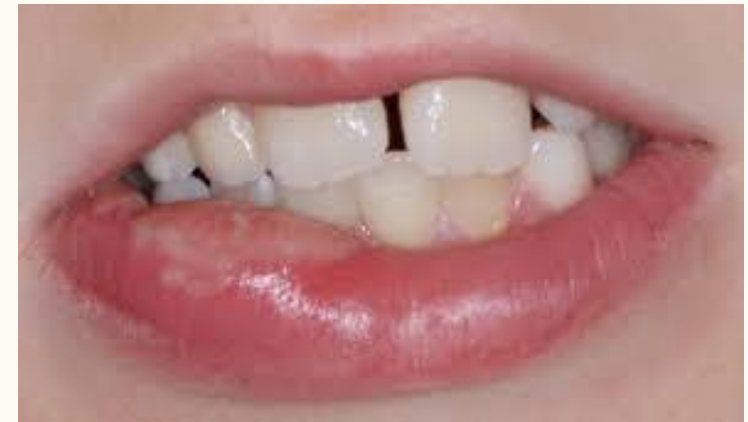[internationaljournalofclinicalpediatricdentistry.com](http://internationaljournalofclinicalpediatricdentistry.com)

# Clinical procedure

- Evaluate the preoperative occlusion
- Crown selection
- Administer local anesthesia
- +/- rubber dam isolation
- Tooth preparation
- Crown adaptation
- Crown finishing and polishing
- Crown cementation
- **Post operative instruction**

## At least for 1 hour avoid:

- **Sticky food: caramel, gum, toffee**
- **Hard substances**





**Thank you**